

Super Detailed Lesson on Body Parts!

Get ready for an incredible journey through the human body! Today, we're going to get up close and personal with every nook and cranny of our physical form. From the top of the head to the tips of the toes, we'll explore the fascinating world of human anatomy. This lesson is packed with over 90 body parts, their pronunciations and fun facts that will make you see the human body in a whole new light. So, let's dive in and discover the wonders of human anatomy together!

The Head

forehead

/fɔːhed/ or /fɒrɪd/

the part of the face above the eyebrows and below the hairline

“She gently touched her **forehead** to check for a fever.”



temples

/ˈtemplz/

the flat areas on either side of the forehead

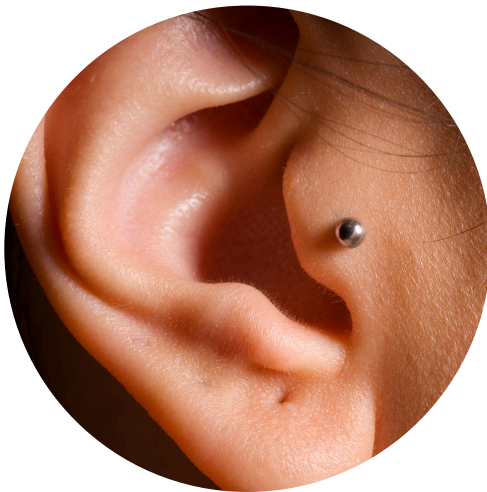“He massaged his **temples** to relieve his headache.”

temporal bones

/ˈtempərəl ˌbəʊnz/

the bones that form the sides and base of the skull

“The **temporal bones** protect important structures in your head.”



tragus

/ˈtreɪɡəs/

the small flap of cartilage at the front of the ear

“She got her **tragus** pierced when she left for university.”

cartilage

/ˈkɑːtɪlɪdʒ/

flexible connective tissue found in various parts of the body

“The **cartilage** in your nose gives it its shape.”

earlobe or **lobe**

/ˈɪələʊb/ or /ləʊb/

the soft, fleshy part at the bottom of the ear

“Jenna wore small stud earrings in her **earlobes**.”

crown

/kraʊn/

the top part of the head

“The **crown** of my dad’s head was starting to go bald.”



scalp

/skælp/

the skin covering the part of the head where hair grows

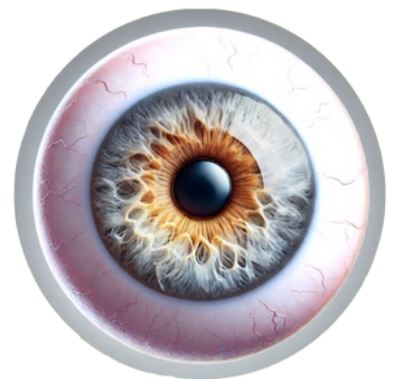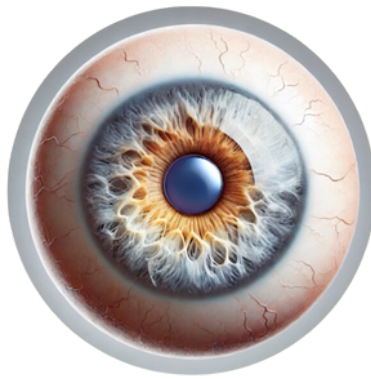
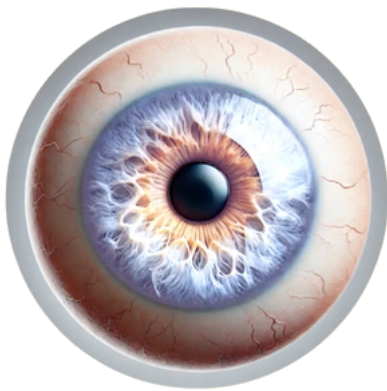“He used a special shampoo to soothe his itchy **scalp**.”

occipital bone

/ɒk'sɪpɪtl bæʊn/

the bone at the back and lower part of the skull

“The **occipital bone** protects the visual processing centre of the brain.”



iris

/aɪrɪs/

the coloured part of the eye surrounding the pupil

“Her bright blue **iris** stood out against her pale skin.”

pupil

/pjuːpl/

the black centre part of the eye that lets in light

“His **pupils** dilated in the dark room.”

sclera

/sklɪərə/

the white part of the eye

“My mum’s **sclera** appeared slightly yellow, indicating a possible health issue.”

eyelid

/ˈaɪlɪd/

the movable fold of skin that covers and uncovers the eye

“Her **eyelid** twitched from lack of sleep.”

eyelashes

/ˈaɪləʃɪz/

the short hairs growing on the edges of the eyelids

“She applied mascara to make her **eyelashes** look longer.”

eyebrows

/ˈaɪbrəʊz/

the lines of hair growing on the ridge above the eyes

“Gerald’s **eyebrows** are so expressive; you always know what he’s thinking.”



glabella

/glə'belə/

the smooth part of the forehead between the eyebrows

"She often gets wrinkles on her **glabella** when concentrating."

frown lines

/fraʊn laɪnz/

also called
11's - /ɪ'levnz/

wrinkles or creases that appear between the eyebrows

"Years of worrying had left deep **frown lines** on his face."

wrinkle

/rɪŋkl/

a small fold or line in the skin, typically caused by aging

"Kim noticed her first **wrinkles** starting to form around her eyes."

dimples

/dɪmplz/

small natural indentations in the cheeks, especially when smiling

"His **dimples** appeared whenever he laughed."

nostrils

/ˈnɒstrəlz/

the two openings of the nose

“She flared her **nostrils** as she caught a whiff of the delicious scent of cookies baking in the kitchen.”

philtrum

/ˈfɪltrəm/

the vertical groove between the nose and upper lip

“The makeup artist highlighted her **philtrum** to enhance her lip shape.”

cupid's bow

/ˌkjuːpɪdz 'bəʊ/

the double curve of the upper lip

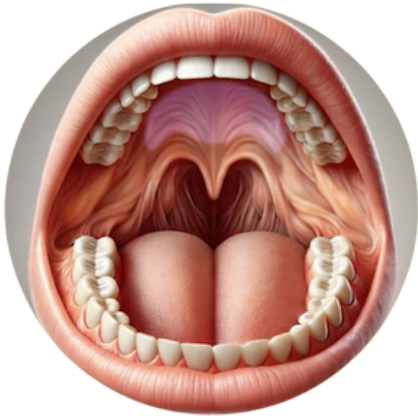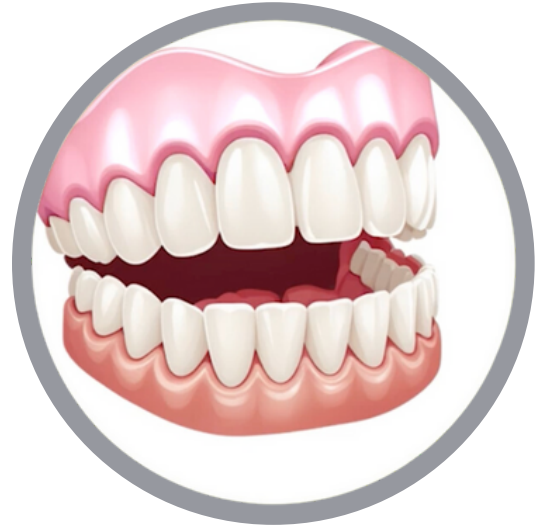“Jasmine’s perfectly shaped **cupid's bow** made her smile even more attractive.”

gums

/gʌmz/

the firm tissue in the mouth that surrounds the teeth

“Brush your teeth gently to avoid irritating your **gums**.”



palate

/pælət/

the roof of the mouth

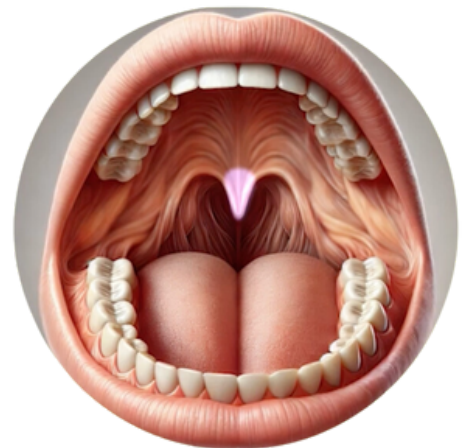
“The hot soup burned my **palate**.”

uvula

/ju:vjələ/

small, fleshy extension hanging from the soft palate

“The doctor examined his **uvula** during the throat check.”





Neck & Shoulders

nape

/neɪp/

the back of the neck

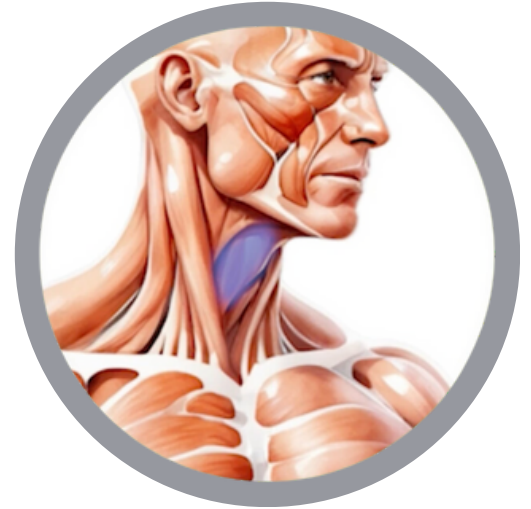“She tied her hair up, exposing the **nape** of her neck.”

Adam's apple

/ˌædəmz 'æpl/

the visible lump formed by the angle of the thyroid cartilage in the neck

“His **Adam's apple** bobbed as he swallowed nervously.”

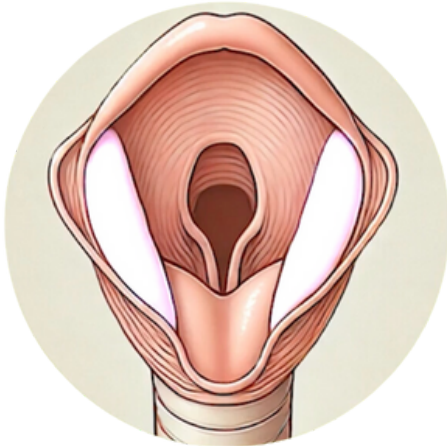


larynx or voice box

/læˈrɪŋks/ or /ˈvɔɪs bɒks/

the hollow muscular organ forming an air passage to the lungs and containing the vocal cords

“The singer strained her **larynx** during the long performance.”



vocal cords

/vəʊkl kɔːdz/

the pair of folded membranes in the larynx that produce speech sounds

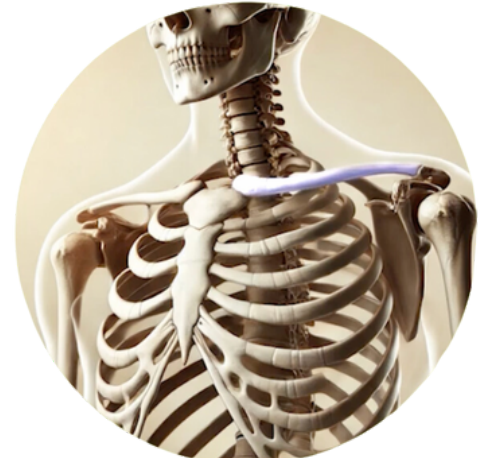“Jazz is going to the doctor’s surgery to have his **vocal cords** examined.”

clavicle

/klævɪkl/

the collarbone

“She fractured her **clavicle** in the bicycle accident.”

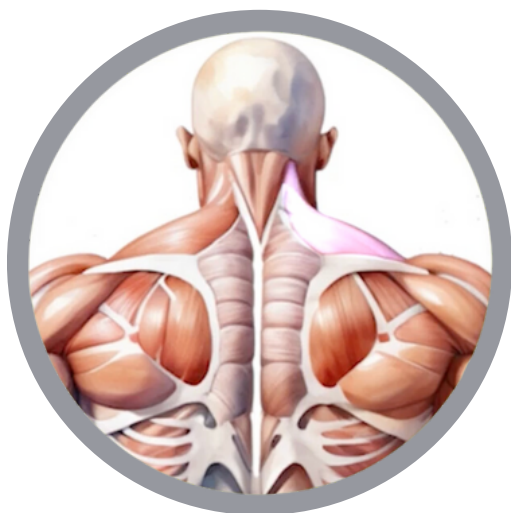

trapezius or traps

/trəˈpiːziəs/ or /træps/

a large triangular muscle extending over the back of the neck and shoulders

“He worked on strengthening his **traps** at the gym.”

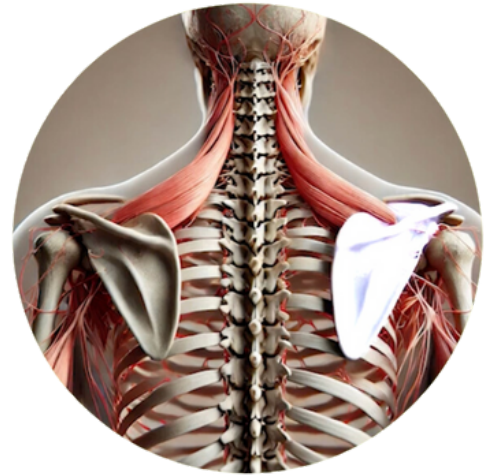

shoulder blades or scapulae

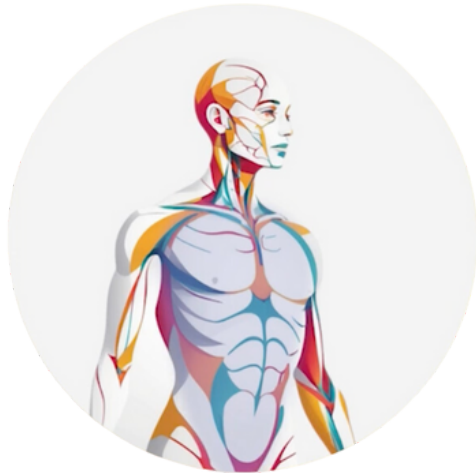/ˈʃəʊldə bleɪdz/ or /ˈskæpjəliː/

large, flat triangular bones in the upper back

“My sister always complain of pain between her **shoulder blades**.”



Torso



torso

/ˈtɔːsəʊ/

the main part of the body

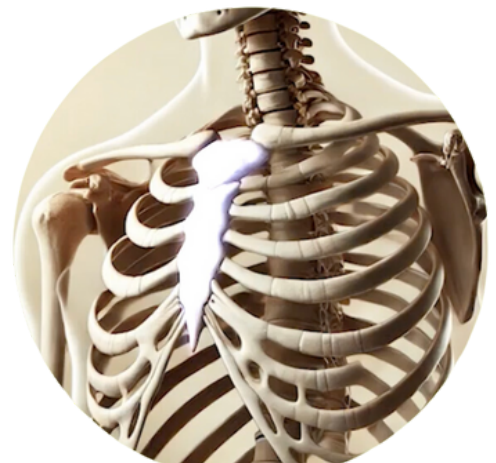“All that survived after all these years was the **torso** of the statue”

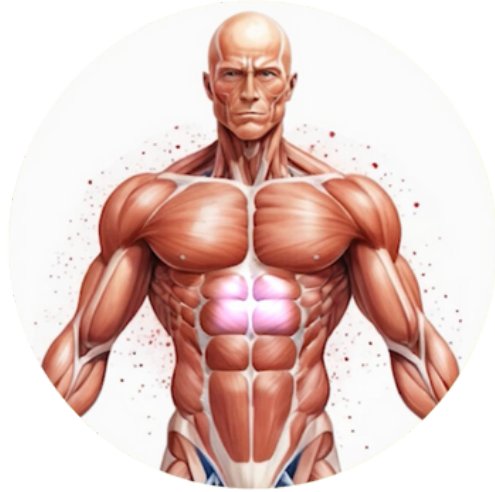sternum

/stɜːnəm/

the breastbone

“The CPR instructor showed them how to locate the **sternum** for chest compressions.”





solar plexus

/ˌsɔʊlə 'pleksəs/

a complex network of nerves located in the abdomen

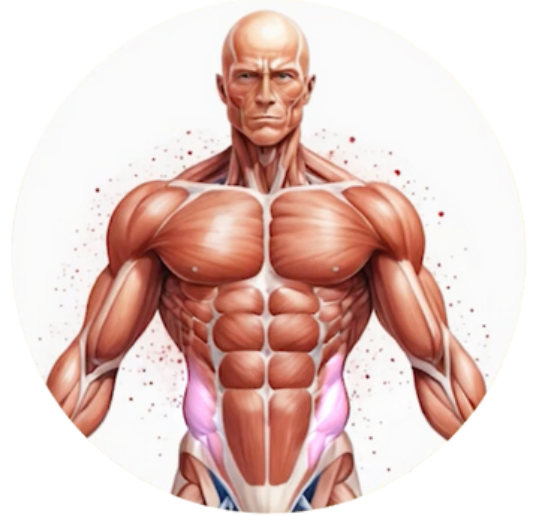“The punch to his **solar plexus** left him gasping for air.”

obliques

/ə'bli:ks/

the muscles on the sides of the abdomen

“They always do side planks to strengthen their **obliques**.”



navel or **belly button**

/neɪvl/ or /beli bʌtn/

the depression or scar in the middle of the abdomen

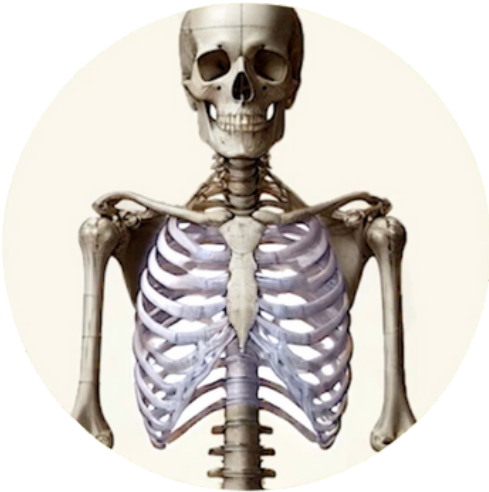“Skyla got her **navel** pierced for her birthday.”

umbilical cord

/ʌmˈbɪlɪkəl kɔːd/

the cord connecting a fetus to the placenta

“The doctor clamped and cut the **umbilical cord** after the baby was born.”

**ribcage**

/ˈrɪbkeɪdʒ/

enclosing structure formed by the ribs

“He felt a sharp pain in his **ribcage** when he coughed.”

floating ribs

/ˌfləʊtɪŋ ˈrɪbz/

the last two pairs of ribs that are not attached to the sternum

“The **floating ribs** provide more flexibility to the lower chest.”



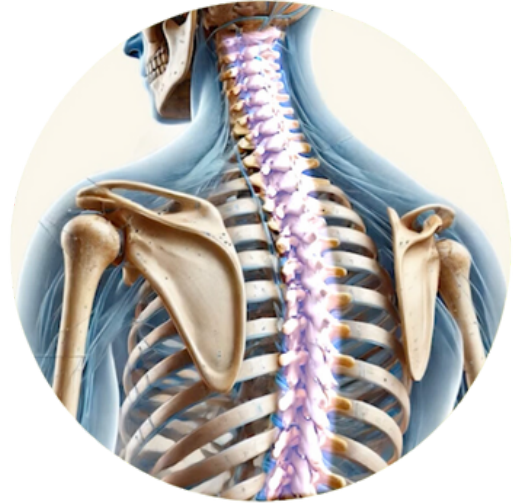Back

spine

/spaɪn/

the series of vertebrae extending from the skull to the pelvis

“Good posture helps maintain a healthy **spine**.”

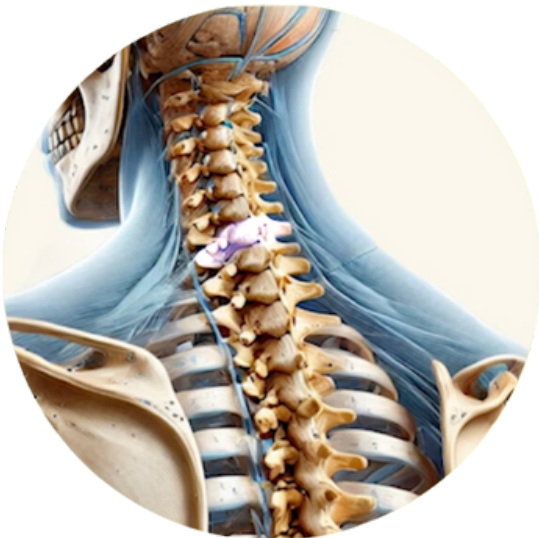


vertebrae

/vɜːtɪbreɪ/ or /vɜːtɪbriː/

the small bones that form the spine

“The **vertebrae** can sometimes fuse together.”



tailbone

cervical

/sɜːvɪkl/
/səˈvaɪkl/

the part of the spine in the neck region

thoracic

/θəˈræstɪk/
/θɔːˈræstɪk/

the part of the spine in the upper back

lumbar

/lʌmbə/

the part of the spine in the lower back

sacrum

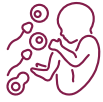/seɪkrəm/
/sækrəm/

the part of the spine at the base

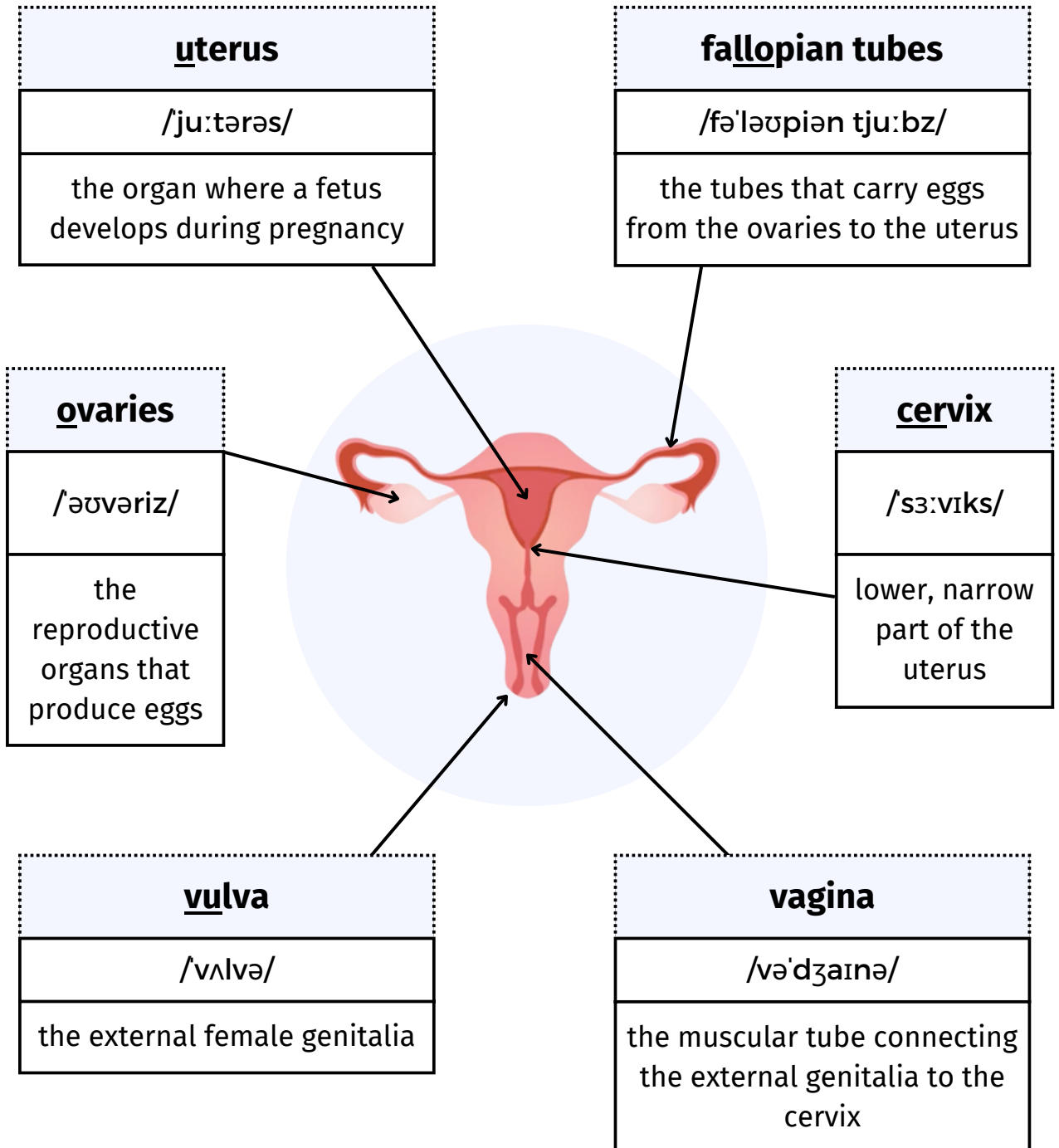
coccyx

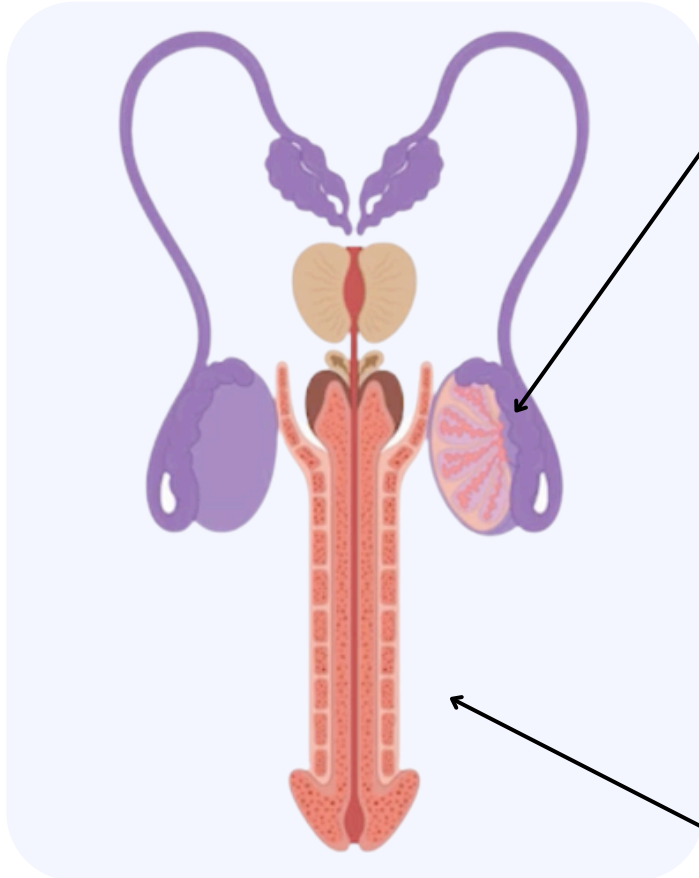
/ˈkɒksɪks/

a small bone at the spine's base



Reproductive System





testises

/ˈtestɪklz/

the reproductive glands that produce sperm and testosterone

penis

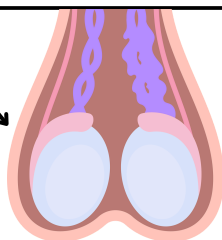
/piːnɪs/

the external male reproductive organ

scrotum

/ˈskrɒtəm/

the external sac containing the testicles





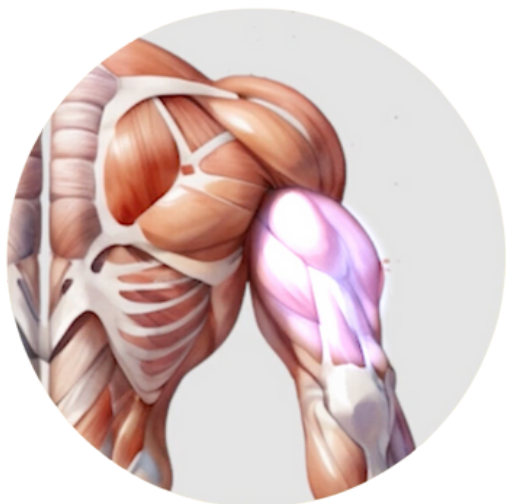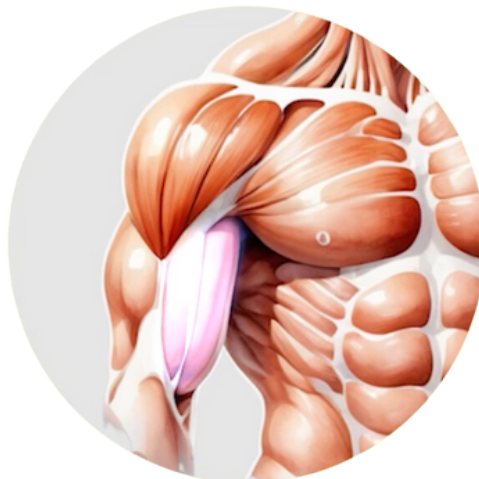Arms & Hands

biceps

/ˈbaɪseps/

the large muscle at the front of the upper arm

"He flexed his **biceps** to show off his strength."



triceps

/ˈtraɪseps/

the large muscle at the back of the upper arm

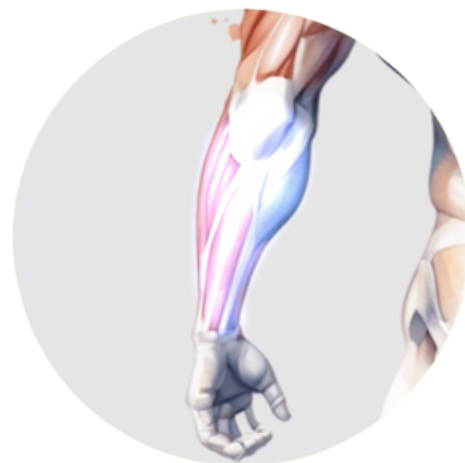
"We do push-ups to work our **triceps**."

forearm

/fɔːrɑːm/

the part of the arm between the elbow and the wrist

"He had a tattoo on his **forearm**."

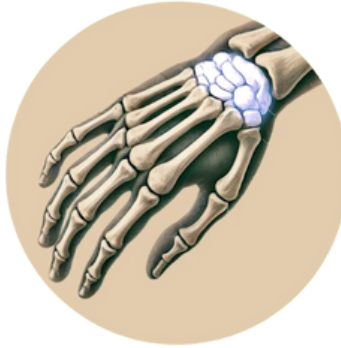

wrist

/rɪst/

the joint connecting the hand to the forearm

“She wore a brace on her **wrist** to support it while typing.”




carpals

/kɑ:pɪz/

the small bones in the wrist

“The X-ray showed that none of the **carpals** were fractured.”



palm

/pɑ:m/

the inner surface of the hand

knuckles

/ˈnʌklz/

the joints of the fingers

fingertip

/ˈfɪŋgətɪp/

the end of a finger

fingernail

/ˈfɪŋgənɛɪl/

the hard layer at the tip of the finger

nail bed

/neɪl bed/

the skin beneath the nail plate

cuticle

/ˈkju:tɪkl/

the skin at the base of a fingernail

Legs & Feet

thigh

/θaɪ/

the part of the leg between the hip and the knee

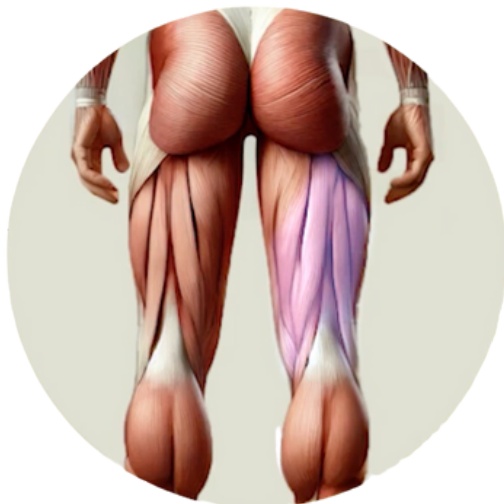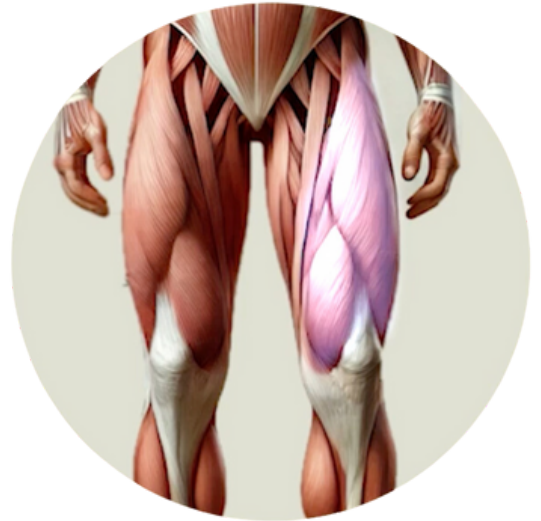
"He felt a burning sensation in his **thigh** after the intense workout."

quadriceps or **quads**

/kwɒdrɪseps/ or /kwɒdz/

the large muscle group at the front of the thigh

"Squats are an excellent exercise for strengthening the **quadriceps**."



hamstring

/hæmstrɪŋ/

any of the tendons at the back of the knee

"The football player injured his **hamstring** during the match."

tendons

/ˈtendənz/

the tough cords of tissue that connect muscles to bones

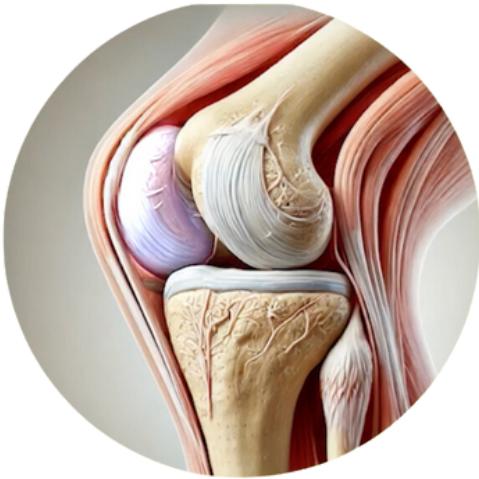“My trainer says I need to work on stretching my tight **tendons**.”

kneecap or patella

/ni:kæp/ or /pə'telə/

the flat, round bone at the front of the knee

“She fractured her **kneecap** when she fell on the ice.”



bursa

/ˈbɜ:sə/

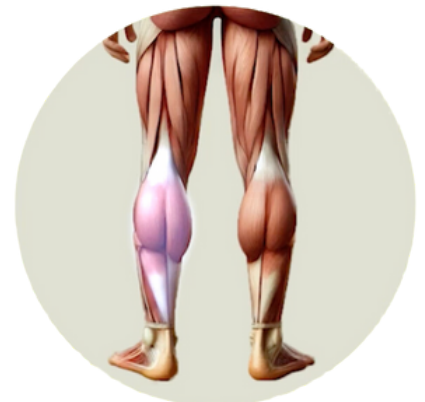a fluid-filled sac that reduces friction between tissues in the body

calf

/kɑ:f/

the back part of the leg below the knee

“My **calves** were sore after leg day!”



tiptoes

/ˈtɪptəʊs/

the tips of the toes

“She stood on her **tiptoes** to reach the top shelf.”

shin

/ʃɪn/

the front part of the leg below the knee

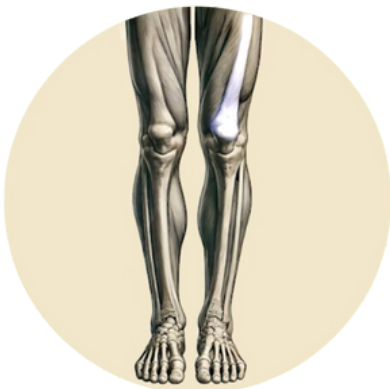“He banged his **shin** on the coffee table.”

tibia

/ˈtɪbiə/

the larger of the two bones in the lower leg

“The **tibia** is the second largest bone in the body!”



femur

/ˈfiːmə/

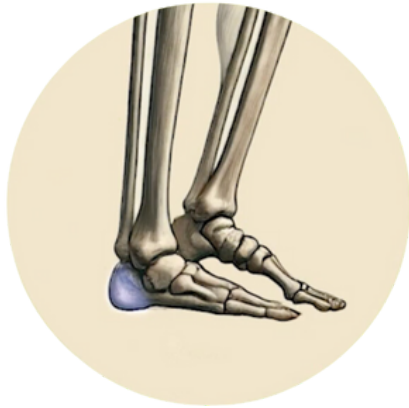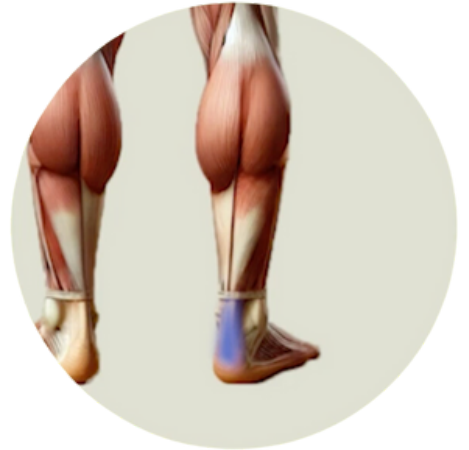the thighbone; the longest bone in the body

Achilles tendon

/əˌkɪliːz ˈtendən/

the strong tendon connecting the calf muscles to the heel

“Many runners suffer from **Achilles tendon** injuries.”



calcaneus

/kælˈkeɪniəs/

the heel bone

sole

/səʊl/

the underside of the foot

“He has a bruise on the **sole** of his foot from stepping on a rock.”

ball

/bɔ:l/

the padded part of the foot just behind the toes

“She felt a sharp pain in the **ball** of her foot while dancing.”

hallux

/ˈhæləks/

the big toe



pinky toe

/ˈpɪŋki təʊ/

the smallest toe

Skin & Hair

pores

/pɔ:z/

tiny openings in the skin

sebaceous glands

/sɪˈbeɪʃəs glændz/

small glands in the skin that secrete an oily substance

sebum

/si:bəm/

the oily substance of the sebaceous glands

freckle

/ˈfreɪkl/

a small, light brown spot on the skin, often becoming more pronounced with sun exposure

“Her face was covered with cute **freckles** across her nose and cheeks.”

mole

/məʊl/

a small, dark, raised growth on the skin

“Benji had a **mole** removed from his back as a precautionary measure.”

pigment

/ˈpɪgmənt/

the natural colouring matter of animal or plant tissue

birthmark

/bɜːθmɑːk/

a coloured mark on the skin that is present from birth

follicle

/fɒlɪkl/

a small secretory cavity or sac, especially one containing a hair root

cowlick

/kəʊlɪk/

a section of hair that grows in a different direction from the rest, often sticking up



Activity

Choose the correct word from the word bank to complete each sentence.

a. scalp	b. freckles	c. navel	d. sternum	e. uvula
f. spine	g. knuckles	h. dimples	i. shin	j. birthmark

1. Proper wrapping technique helps protect a boxer's _____, the joints of the fingers, from injury during fights and training.
2. The _____ is the flat bone in the middle of your chest that protects your heart.
3. The _____ is where hair grows from on the head.
4. Many babies are born with a _____ somewhere on their skin.
5. The _____, also known as the belly button, is where the umbilical cord was attached before birth.
6. Sun exposure can increase the appearance of _____ on your face and arms, though they are usually harmless.
7. The team's striker is out for two weeks after a tackle left him with a bruised _____. This front part of the lower leg is particularly vulnerable in football.
8. Maintaining good posture is crucial for a healthy _____. This column of bones supports your entire body.
9. Did you know that your _____ helps prevent food from entering your nose when you swallow? This small, hanging structure at the back of your throat plays a crucial role in eating and speaking.
10. Fans adore the actor's charming _____, those small indentations that appear on his cheeks when he smiles.

Answers:

1.g.2.d.3.a.4.j.5.c.6.b.7.i.8.f.9.e.10.h

